

POLYNEUROPATHY TREATED WITH CLASS IV THERAPY LASER

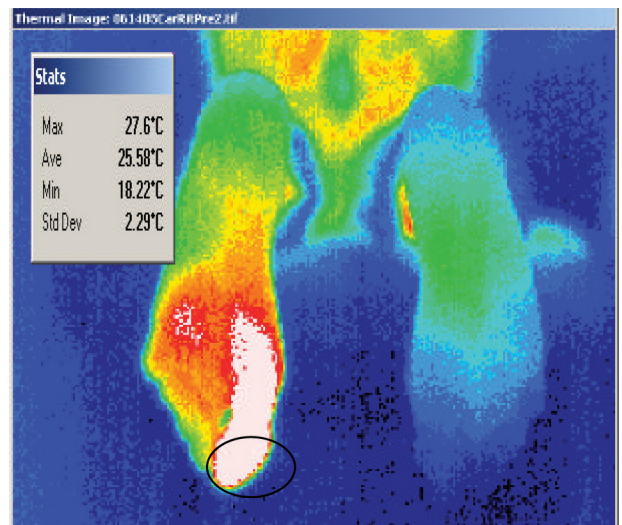

Authors: Craig A. Mueller, DC, CACBII, Jerry Koziej, DC, CSP

CLASS IV LASER THERAPY CASE REPORT

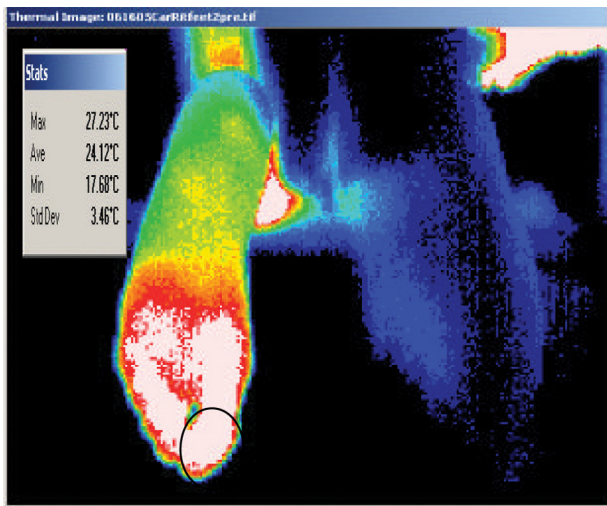
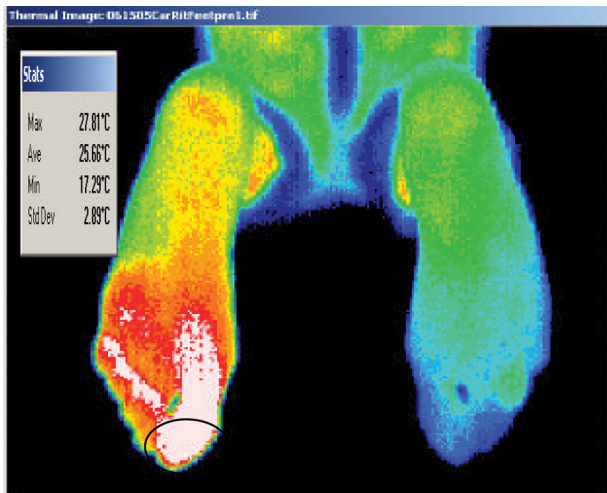
High resolution Digital Infrared Thermal Imaging reveals radiation emission patterns emitted by the microcirculation in the skin. The sympathetic nervous system ultimately controls this function though it is influenced by central and local stimuli as well. The image above is the plantar surface of the feet of a 52 year old female. Her medical diagnosis upon presentation was small fiber sensory polyneuropathy. Her symptoms began in November 1998 and did not involve a specific injury. She recalled the burning sensations originating in both feet one year after she began taking Statin drugs. Additionally, she was walking approximately 90 minutes per day on a treadmill to combat elevated cholesterol levels. She reported the muscular spasms in her legs to her prescribing doctor and her meds were changed to various Statins before being suspended in January 2000. The May 14, 2002 edition of American Journal of Neurology published the results of a Danish study claiming that people taking Statin drugs were 14 times more likely to develop a peripheral neuropathy than those not taking the drug. Subjects in the Danish study took Statins for an average of 2.8 years. In this case, discontinuing the Statin drugs did not reverse her condition; her pain progressed. One year into her Statin treatment burning pain dominated her feet. A year later her feet and ankles began to swell. As the condition progressed, she described her pain as “standing in scalding water.” When the image above was made, the skin tone on each foot was purple. The thermographic significance in this image is the

localized hyperthermic pattern over the proximal interphalangeal joint on the left foot.

This case illustrates how advances in this technology assist the doctor in arriving at a proper diagnosis, localizing treatment and monitoring response to care. These images are intended to show the rapid and demonstrable impact a Class IV therapeutic laser had on vasomotor stability resulting in a dramatic reduction in pain and disability.



877-817-0365 • info@aspenlasers.com • aspenlasers.com



The images to the above were recorded before Class IV laser treatment began on days two, three and four respectively. Each session lasted fifteen minutes, involved a continuous 7.5 watt output through a 7 cm/ diameter beam and a 980nm bandwidth. A 7.3 degree difference is recorded between the toe great toes.

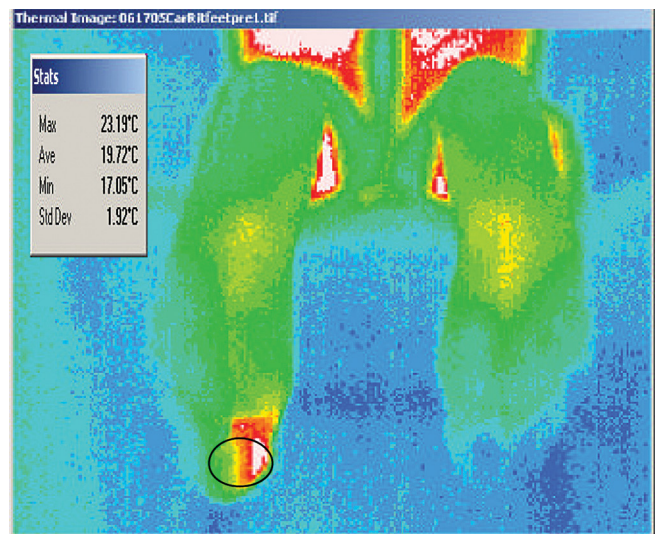
Treatment to the right foot was decided on for many reasons. First, although the most remarkable finding was on the left foot, there was no indication a localized injured had occurred at that level. Second, the patient could not recall pain specifically emanating from that location. The history indicated the condition began following another chemical insult to the peripheral nervous system resulting in hypersensitization or Cannon's phenomenon. Theoretically this predisposed the nerves at the PIP joint on the left great toe to

mechanical insult during ordinary locomotion, as the patient described, resulting in an emerging "Angry Backfiring C fiber" as described by Ochoa. Additional consideration in selecting the right foot was given to the depth the Class IV laser could penetrate as well as the high wattage photochemical sensory input to the peripheral afferent pathways and the observable efferent response in the left foot. Finally, for practical purposes, treatment to the right foot would serve as a control measure in the event the desired outcome was not achieved and subsequent treatment was applied to the PIP on the left great toe.

While the right foot warmed slightly, the left PIP expanded beyond the original borders and followed the vascular course across the foot surface. The beam to the right foot was applied in a slow, sweeping, "paintbrush" fashion. Laser treatment was limited to the right foot only for the first five days.

Visible reaction confirms the afferent/efferent sympathetic pathways do receive and transmit information. The patient tolerated all therapy without any adverse consequence. By the third day, the right foot is showing improved vasomotor stability and a more normal skin tone is observed on both feet.

The bottom view shows the persistent dilation in the left great toe and plantar surface and the right foot is now reacting to the ambient cold temperature. Objective visible stability is not confirmed in spite of the patient's encouraging subjective remarks.

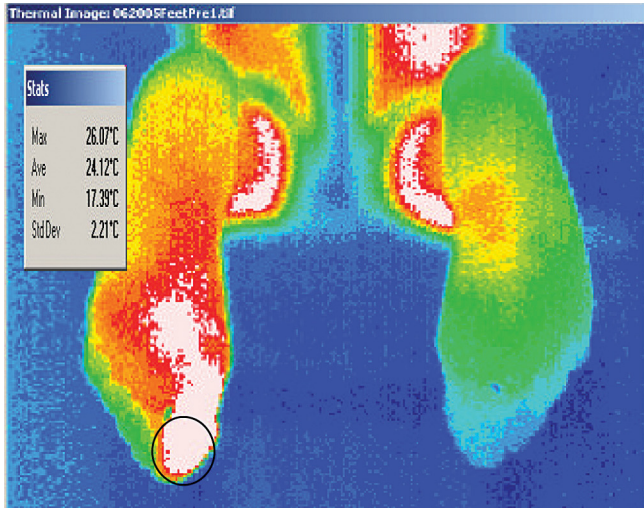


ASPEN

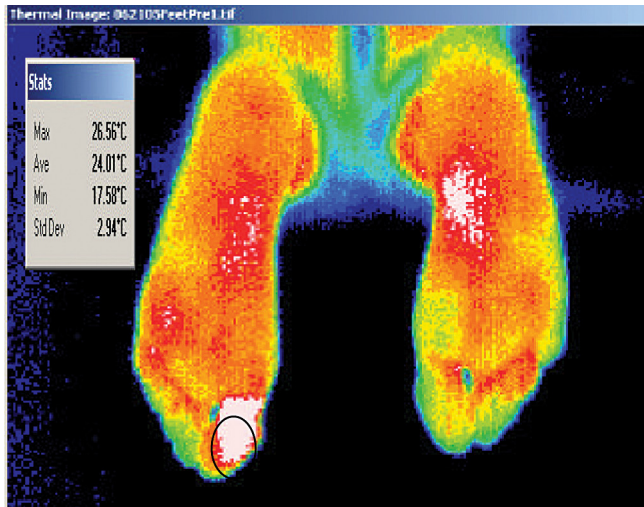
L A S E R S Y S T E M S

877-817-0365 • info@aspenlasers.com • aspenlasers.com

The top view reveals the plantar surface following four consecutive daily Class IV laser applications. The thermal balance between the two feet, save the remaining focal hyperthermia on the left PIP, is impressive given that all treatment was applied to the right foot.

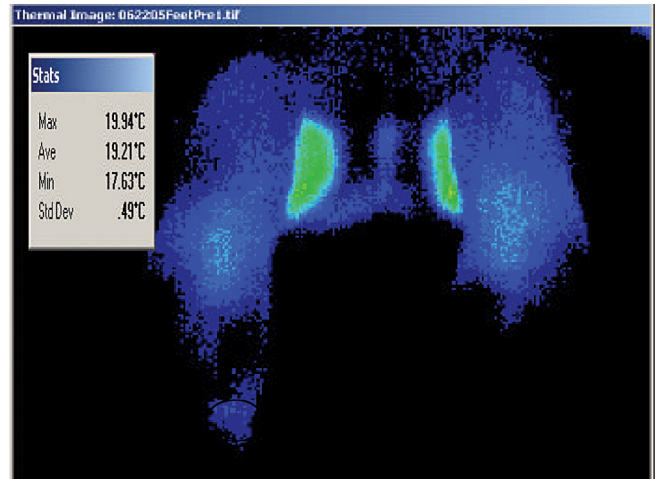


This view was taken four days later. The patient felt so well she went shopping for two hours; the first time in many years. Afterwards the burning came back in the feet with a vengeance. Following this scan, treatment was directed to the left foot for the first time.

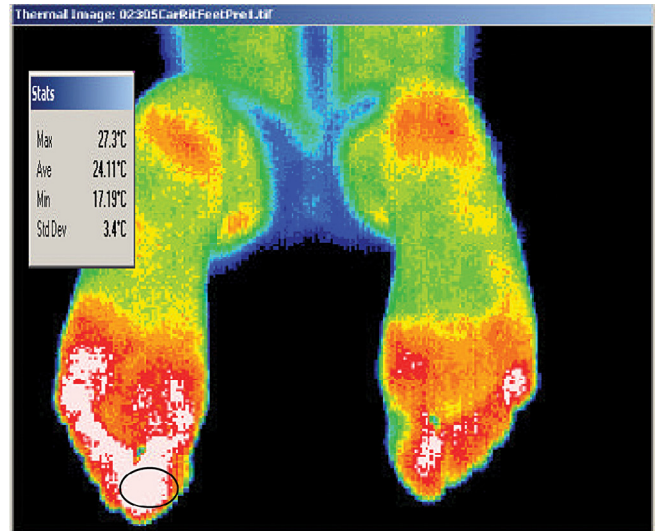


This image represents one day post left foot laser therapy. The first laser treatment to the left PIP on the great toe yielded the most remarkable subjective

response by the patient. The temperature differential between the two great toes is 2.3 degrees C.



This image is before the third treatment to the left PIP in the great toe. Her feet at rest look perfectly normal, the best they have in years, and her pain level is dramatically reduced. She can now tolerate the air-conditioning in the car blowing onto her feet; she was totally intolerant to cold air on her feet when the laser was applied to the right foot. A true indication of the vasomotor volatility, in the top view both feet are now responding to the ambient temperature; the actual temperature over the left PIP in the great toe is down six degrees from the initial scan nine days earlier.



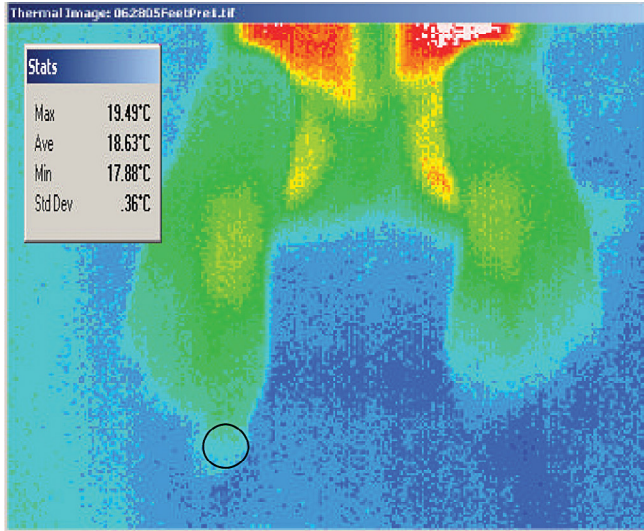
This image was made on day four of treatments to the left foot. Three consecutive Class IV laser treatments reveal the two plantar surfaces are demonstrating

ASPEN

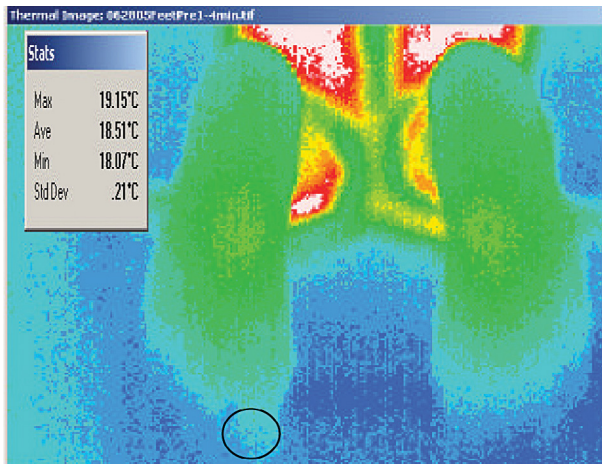
L A S E R S Y S T E M S

877-817-0365 • info@aspenlasers.com • aspenlasers.com

the best graduated thermal gradient pattern to date. The patient notes her feet do not burn during the day, they “buzz.” She continues to have some burning only in the middle of the night. At this time she is taking one Neurontin versus one every five hours. Her psychological outlook is much improved and she is already enjoying marked improvement in her activities of daily living.

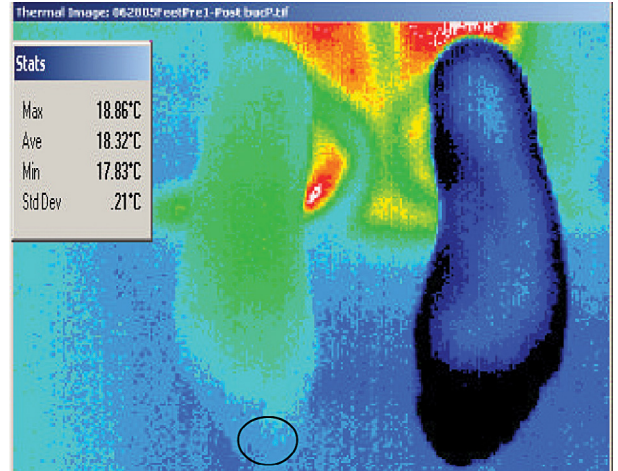


This is the pre-laser scan taken five days later. Given the marked response the patient related, the resolution to the PIP on the left great toe and a temperature differential between the two great toes was less than one half degree C, no laser therapy was applied. A “wait -and-see” approach was taken.

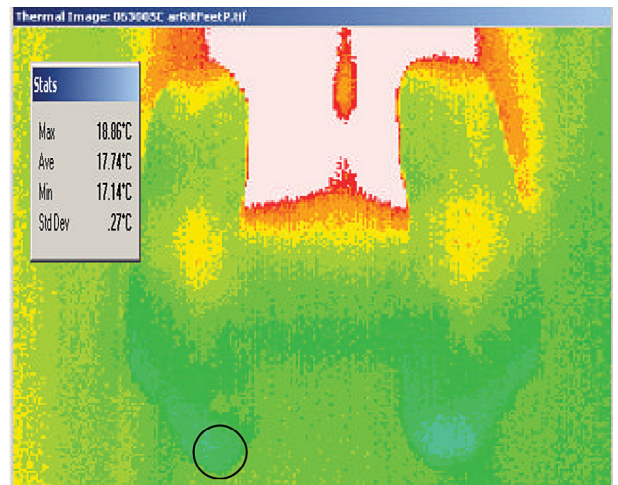


On the same day as the “wait-and-see” approach was taken, a cold challenge was applied to the patient’s

sympathetic nervous system by having her hold a frozen soda can in each hand. The image to the left was made after four minutes.



This image, made the same day, was made four minutes following another cold challenge. Here the patient placed her right foot in a bucket filled to the lower ankle with water chilled to 40 degrees C. Aside from the cold water, the patient experienced no discomfort or reaction in her left foot. As the foot warmed there was no reaction as she experienced over the previous years.



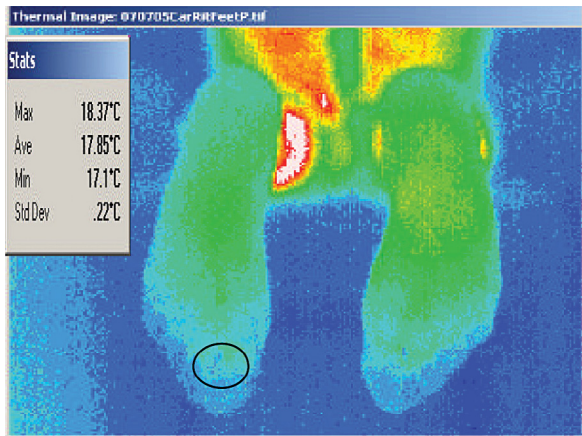
This view is two days post “cold challenge” and the great toe differential is now at .25 degrees C. She continues to enjoy a more normal appearance to her feet throughout most of the day. Even when the color changes slightly she does not experience the dramatic corresponding pain. Her feet still burn in the middle of

ASPEN

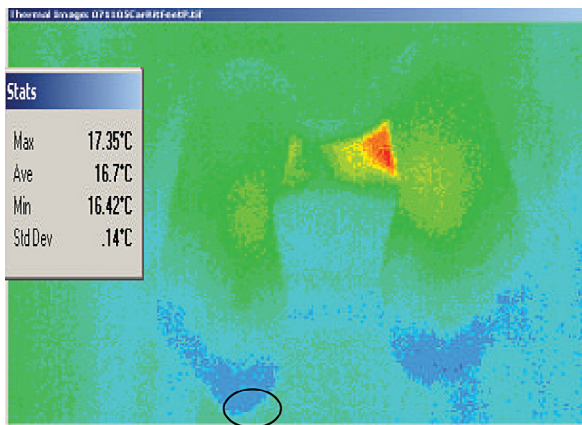
L A S E R S Y S T E M S

877-817-0365 • info@aspenlasers.com • aspenlasers.com

the night although they are fine when she wakes up in the morning. She does not demonstrate the sympathetic dominance she once did via hyperhidrosis in either the hands or the feet. Further investigation into her hormonal and glucose levels is underway. She has not received any additional laser treatment for one week at this point.



This view is two days post “cold challenge” and the great toe differential is now at .25 degrees C. She continues to enjoy a more normal appearance to her feet throughout most of the day. Even when the color changes slightly there is not the dramatic corresponding pain. Her feet still burn in the middle of the night although they are fine when she wakes up in the morning. She does not demonstrate the sympathetic dominance she once did via hyperhidrosis in either the hands or the feet. Further investigation into her hormonal and glucose levels is underway. She has not received any additional laser treatment for one week at this point.



This image is one week later, now three weeks following her last laser therapy. This person states she is now functioning better than she has since November 1998. To this point she has had only four treatments to the PIP on her left great toe with a continuous-beam Class IV therapeutic laser.

After initially treating the right foot, and observing changes in both feet, it was apparent the sympathetic sensory fibers perceived the photochemical reaction. That the patient noticed an improvement she had not seen in years, the skin began to look more normal, less cyanotic. The temperature differential was unimpressive and I did not hold out much hope the improvement would last long. The poor response to her efforts to walk on hard level surfaces confirmed my suspicion. The original plan was to apply the therapy to the right foot for the first week, so the reaction she experienced over the weekend did not trigger a change in treatment to the left foot. The hyperthermic response to the left PIP in the great toe suggested the neurovascular change there may be revealing an ephaptic peripheral nerve damage. The dramatic response to vasomotor stability, although not perfect, indicated the PIP on the left great toe was a critical neurological lesion. In a small unmyelinated nociceptor such a reaction could be labeled an “angry back firing C fiber.” As mentioned earlier, even this diagnosis was tentative because there was no localized pain over that location nor was injury to that location reported. However, Livingston’s “vicious cycle” suggest the hyperactivity of the anterolateral horn motor cells in the spinal cord is caused by decreased input from larger proprioceptors. Livingston also noted several chemical forms of the vicious cycle, the one most suspected in this case was cholinergic stimulation which results in hyperhidrosis. This resolved with treatment. Therefore, it is concluded that although the patient is on nutritional supplementation to influence sympathetic dominance, the laser therapy was the catalyst in affecting change. The right foot did in



877-817-0365 • info@aspenlasers.com • aspenlasers.com

fact serve well as a control measure. Consequently, it appears the Class IV laser therapy accelerated localized tissue recovery which in turn enabled a complete neurological circuit to bring vasomotor and sensory stability to both feet.

While concomitant physiological issues contributing to her altered physiology require ongoing investigation and treatment, Infrared Imaging has proven once again why it is the only imaging method to reveal functional changes in peripheral vascular conditions involving neuropathic pain. Any clinician addressing persons plagued by acute and chronic pain will appreciate an invaluable tool to safely, efficiently, and economically monitor peripheral vascular function as a therapeutic modality is employed. Anatomical studies such as MRI, CT, or standard x-ray lack the capacity to reveal function in the sympathetic nervous system. Likewise, no therapeutic modality aside from a continuous beam Class IV laser has the ability to penetrate surface and deep tissues. This case objectively illustrates how properly locating the involved tissue and applying the proper therapy brings about the best response, predictably and economically in term of dollars spent and production lost. Until this technology is more readily utilized in the medical market place the spiraling cost to treat chronic somatic and neuropathic pain will undermine the patients health and further tax a crippled health care delivery system. Closer to home, unexpected or ongoing medical expense is the number one reason for personal bankruptcy today. Therefore, digital infrared imaging and Class IV laser therapy have the potential to stop the pain in more ways than one!

ABOUT THE AUTHORS

Dr. Koziej is a native of Dayton, OH and has practiced at Mueller Chiropractic since 1996. He once rode his bicycle across America and has since remained physically fit. Today he helps competitive athletes and weekend warriors heal through his expertise in biomechanics. Dr. K was one of the first in Kentucky to master Class IV Laser Therapy and utilizes it to complement his expertise in spinal adjusting techniques.

Dr. Craig Mueller earned a chiropractic degree from Logan University. In addition to mastering many chiropractic adjusting techniques, he extensively studied biochemistry and the benefits of sound nutrition. Dr. Mueller received a Fellowship in Applied Spinal Biomechanical Engineering, Certification In Advanced Diagnostic Imaging and ultimately Board Certification In Infrared Imaging. He is the author of *The New Chiropractic: The Human Frame, Diet, Exercise and the Prevention of Disease*.

Source of Study: AspenLasers.com



877-817-0365 • info@aspenlasers.com • aspenlasers.com